Neurological Manifestations of Tuberous Sclerosis Complex (TSC) and Treatment with mTOR Inhibitors

Darcy A. Krueger, MD PhD
Director, Tuberous Sclerosis Clinic
Cincinnati Children's Hospital Medical Center

TSC Symposium be-TSC vzw
Leuven, Belgium
16 November 2019

Cincinnati Children's
changing the outcome together

Disclosures

- Novartis Pharmaceuticals
- Upsher-Smith Pharmaceuticals
- Greenwich Biosciences

- National Institutes of Health
- TS Alliance
- Clack Foundation

Cincinnati Children's
changing the outcome together

Tuberous Sclerosis Complex: Brain



Sclérose tubéreuse des circonvolutions cérébrales

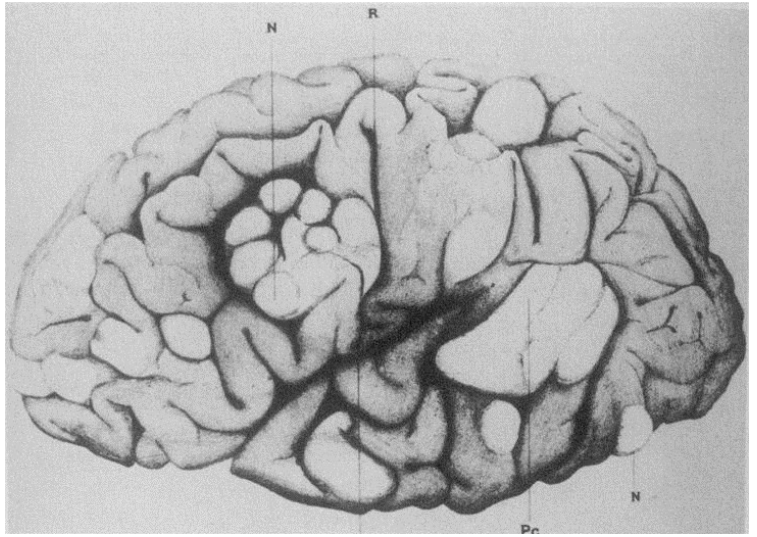

Désiré-Magloire Bourneville
1881

Structural Lesions of the Brain in TSC

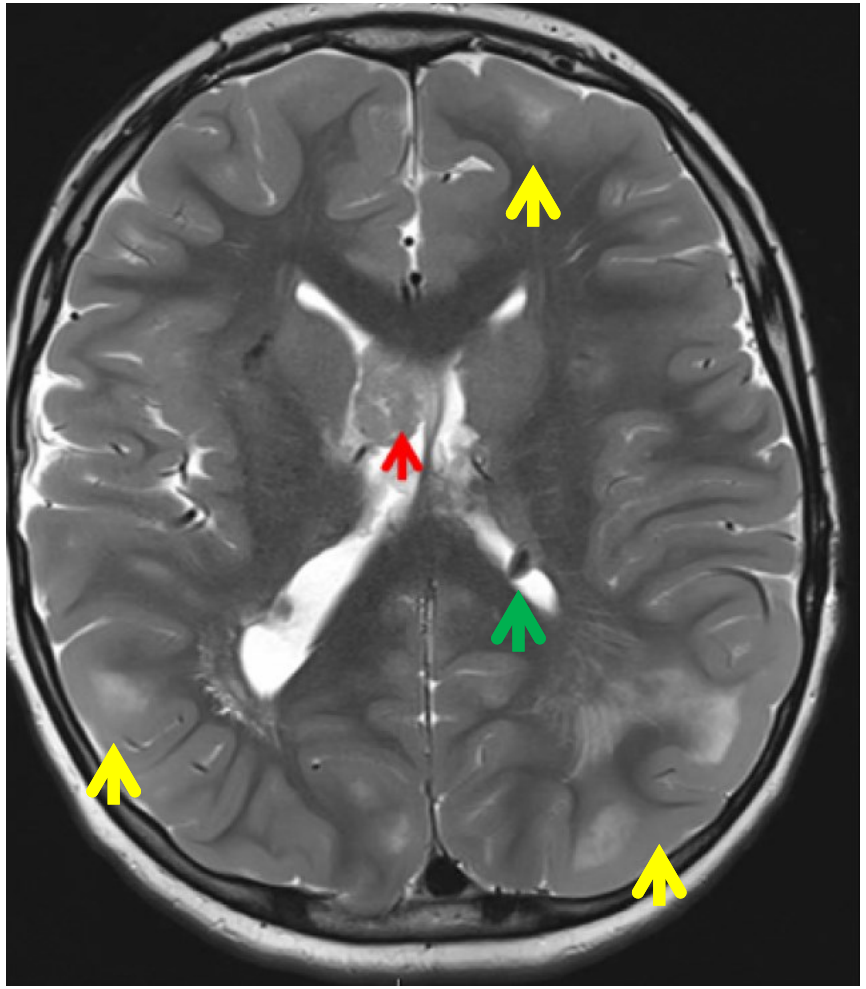

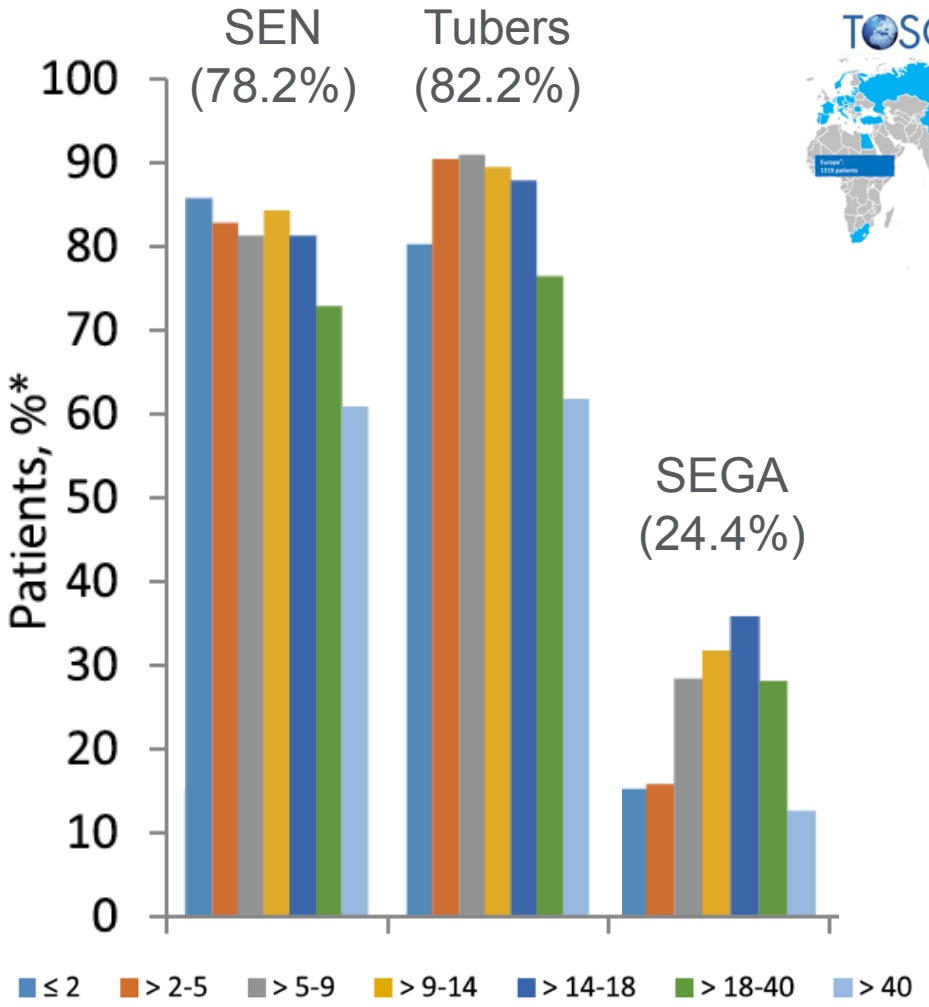



Kingswood et al. *Orph J Rare Dis. (2017) 12:2*

Clinical Manifestations of the Brain in TSC

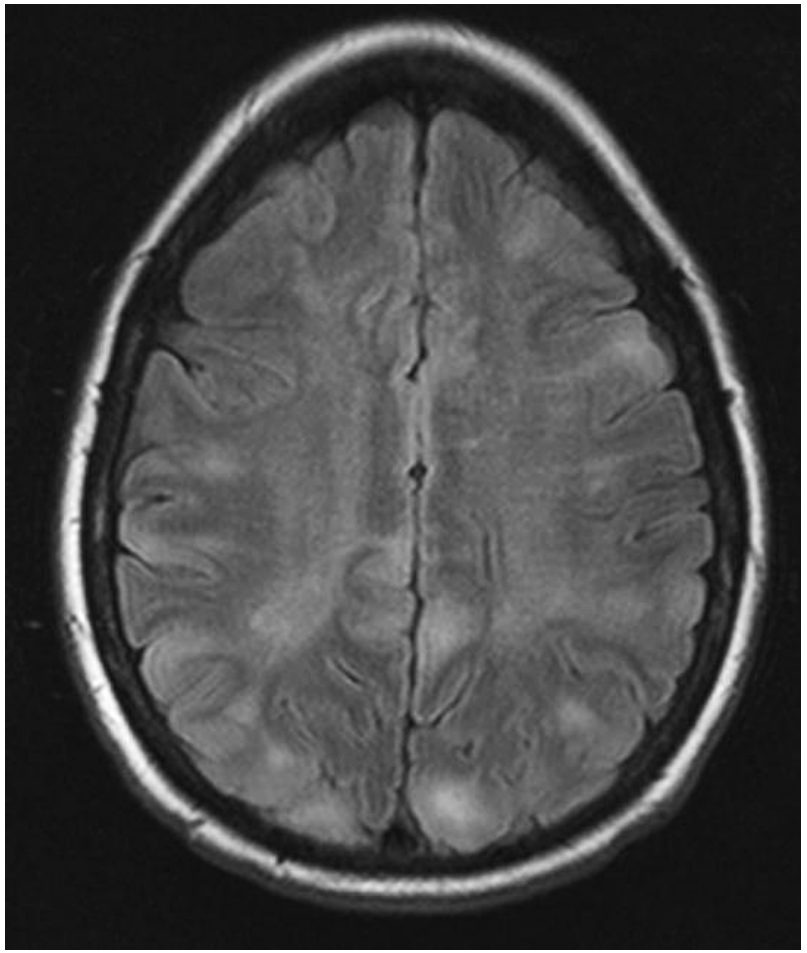

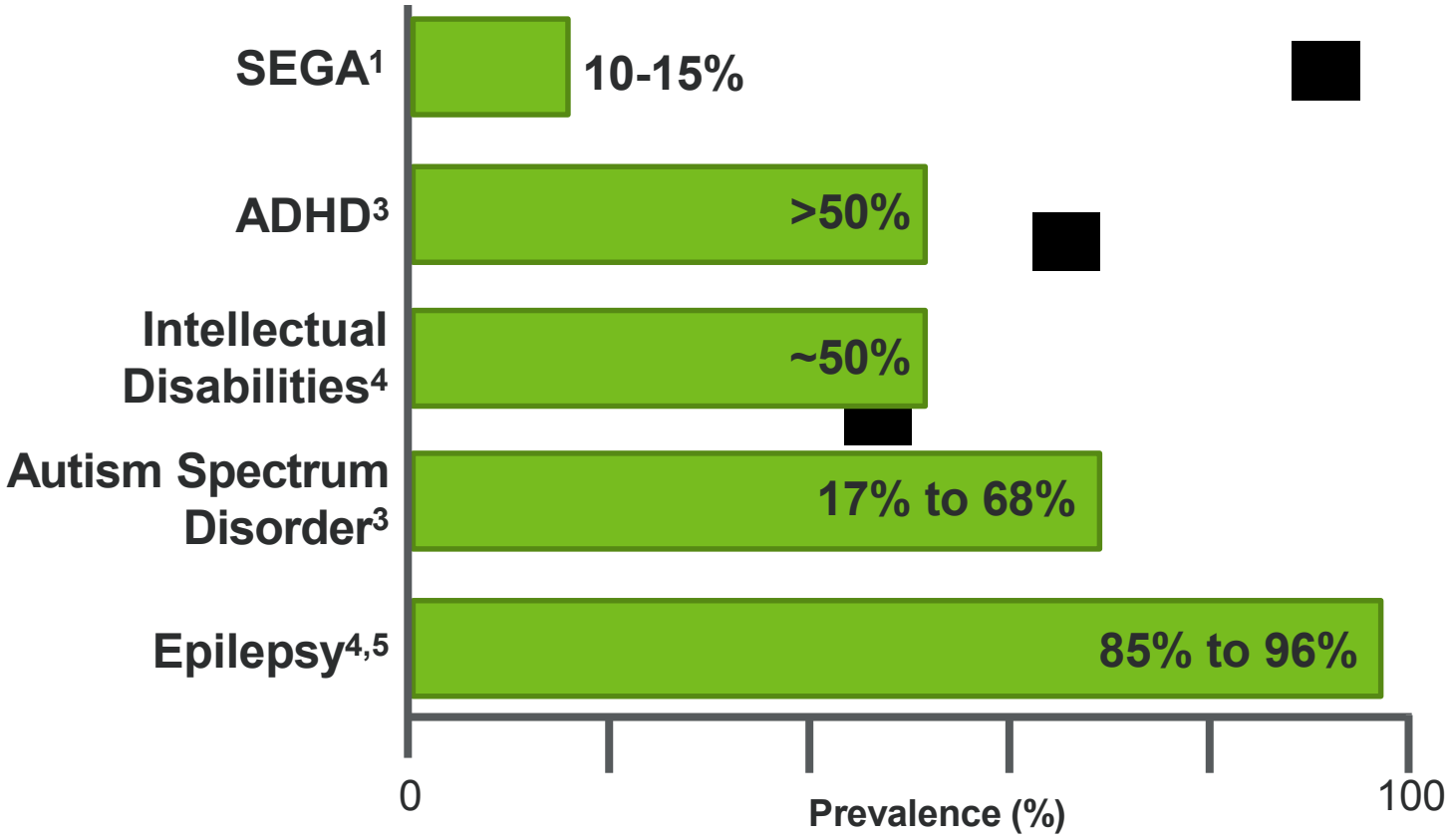

ADHD, attention-deficit\ hyperactivity disorder; TSC, tuberous sclerosis complex. SEGA, subepnedymal giant cell astrocytoma

1. Roth et al. *Pediatr Neurol* 2013; 49:439-44. 3. Kopp CM et al. *Epilepsy Behav.* 2008;13:505-510. 4. Ehninger D et al. *J Intellect Disabil Res.* 2009;53:838-851. 4. Chu-Shore et al. *Epilepsia*. 2010;51:1236-1241. 5. Jóźwiak et al. *J Child Neurol*. 2000;15:652-659

Cincinnati Children's™
changing the outcome together

Subependymal Giant Cell Astrocytoma (SEGA)

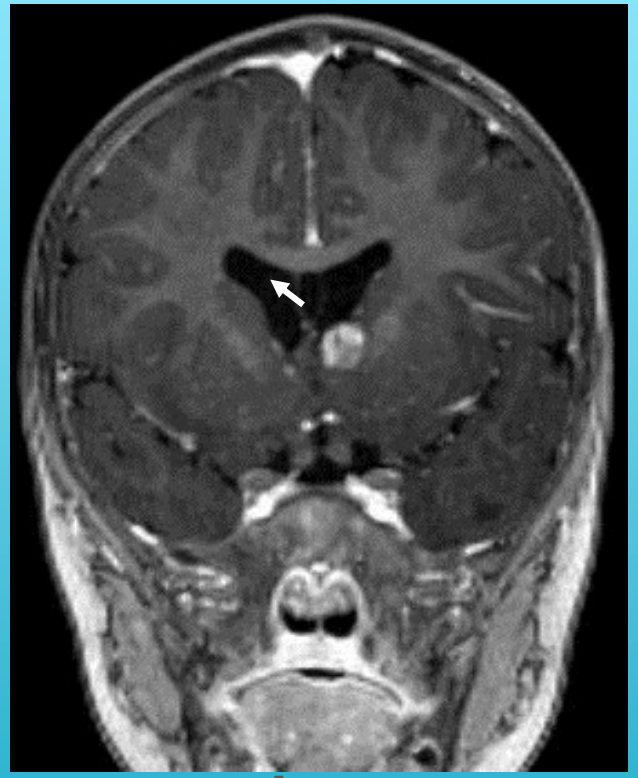

Age:
2.3 years

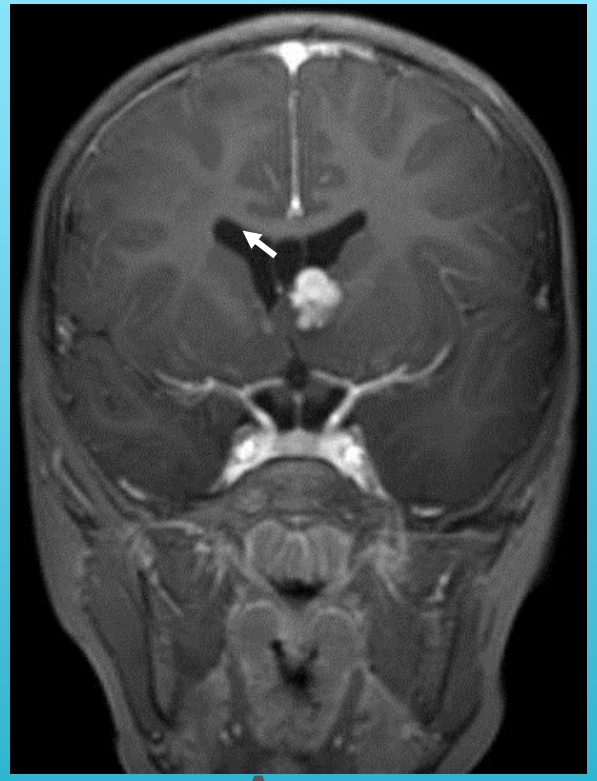

Age:
3.0 years

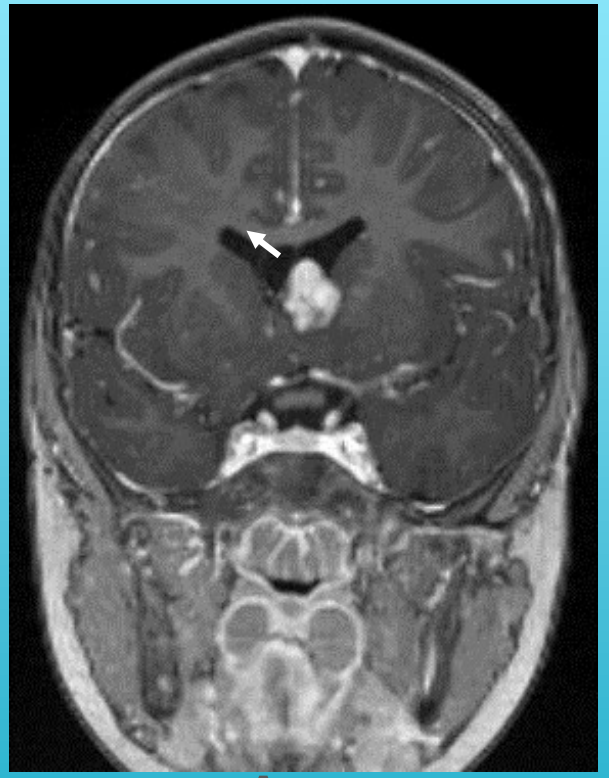

Age:
3.5 years

Subependymal Giant Cell Astrocytoma (SEGA)



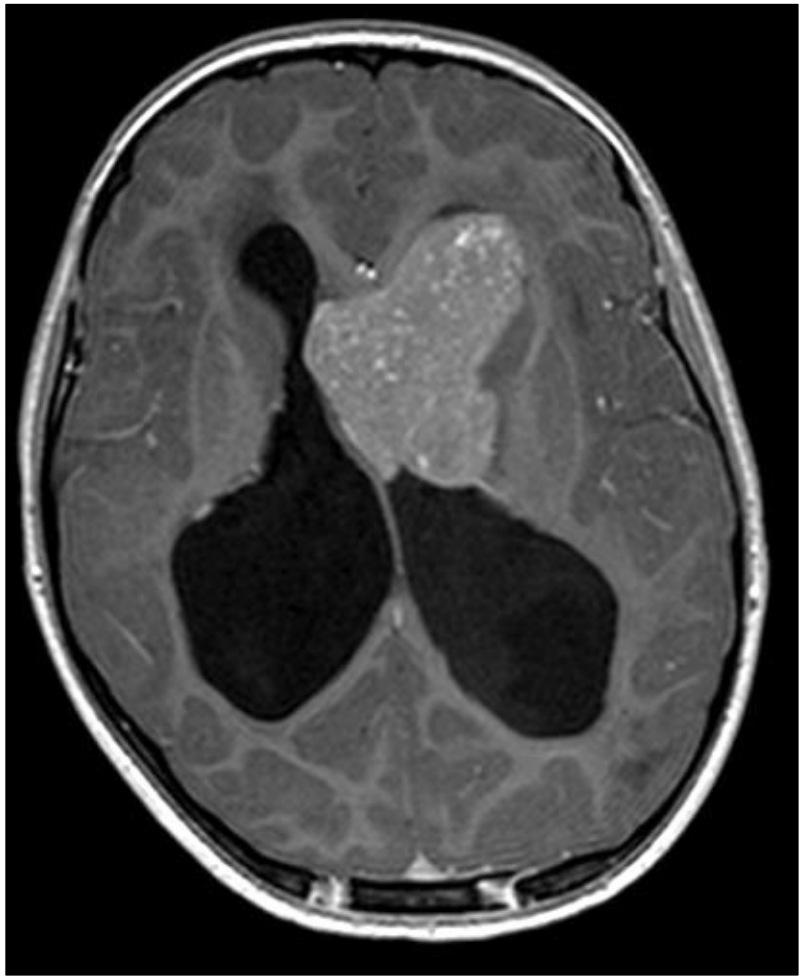

Subependymal Giant Cell Astrocytoma (SEGA): Surgical Resection

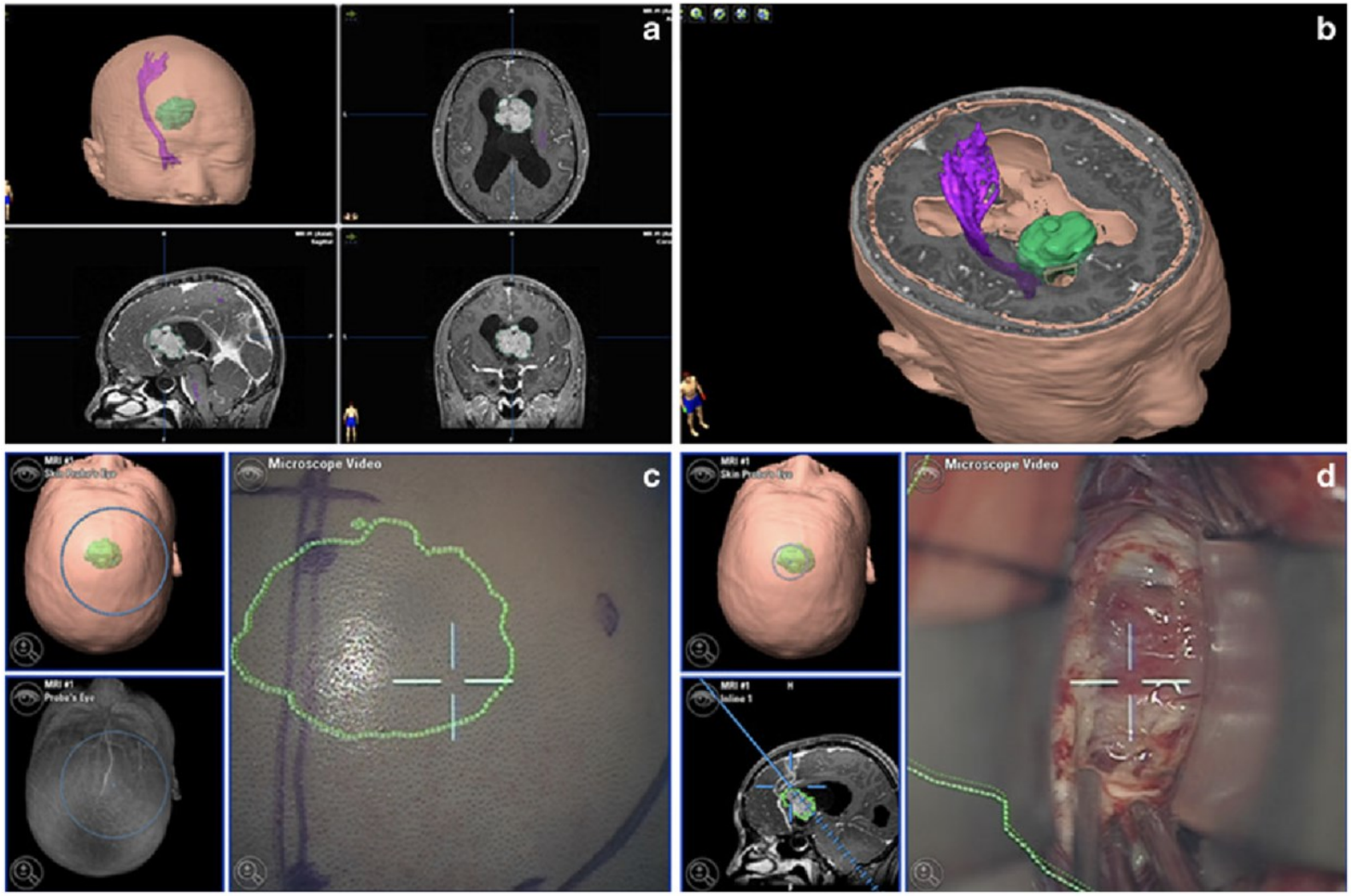

Ren et al. *Childs Nerv Syst 2013; 29:1113-21*

Subependymal Giant Cell Astrocytoma (SEGA): Recurrence after subtotal surgical resection

Presentation

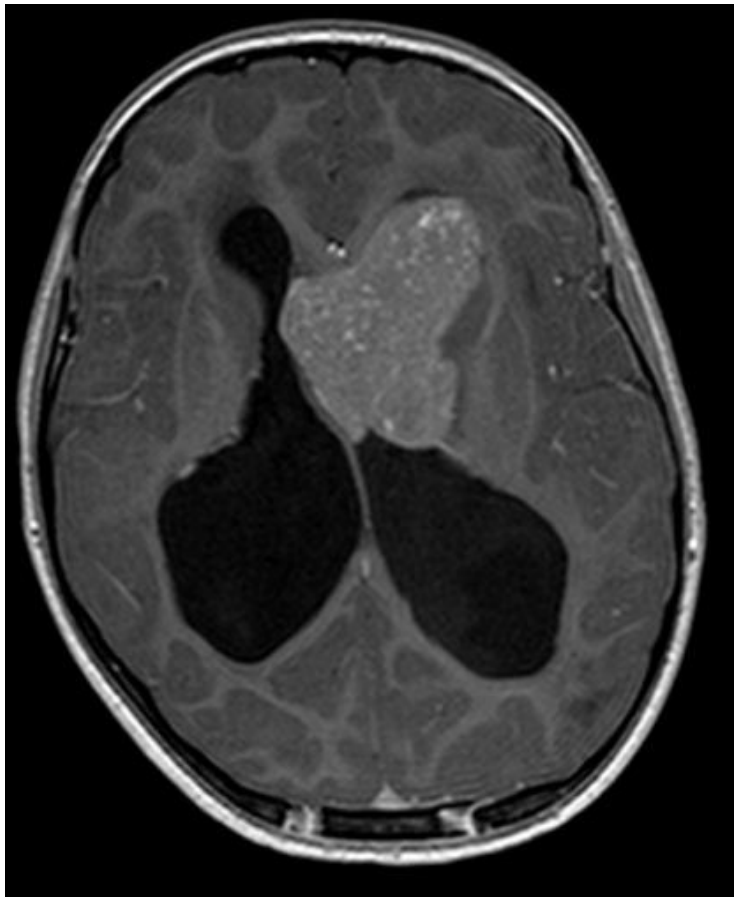

Post-Operation

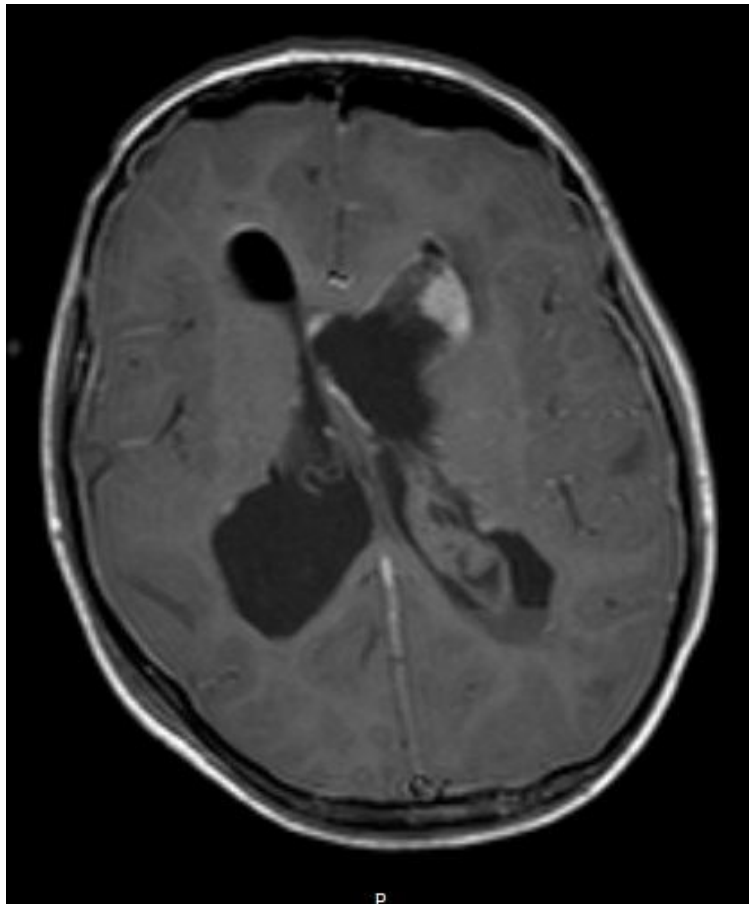

Follow-up (3 mo)

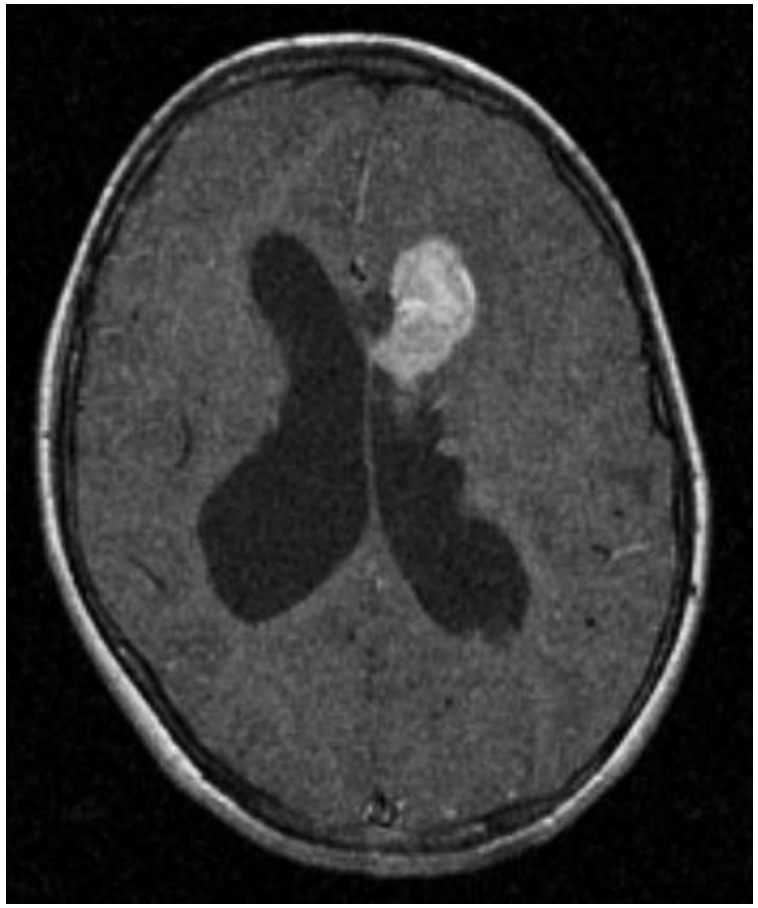

Subependymal Giant Cell Astrocytoma (SEGA): Reasons for Alternative to Surgery?



Congenital SEGA

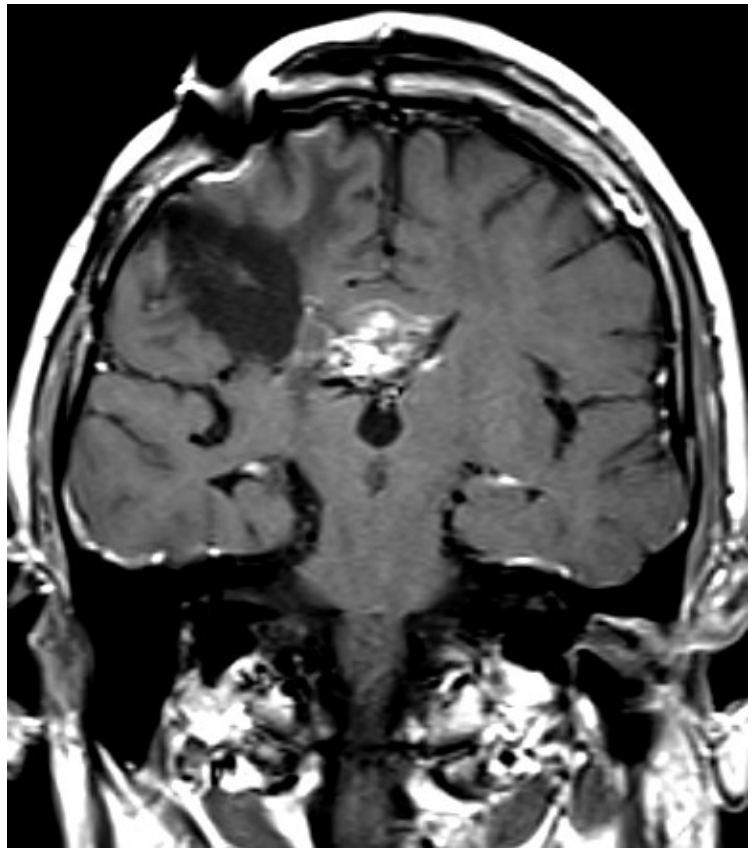

Post-Surgical Complications

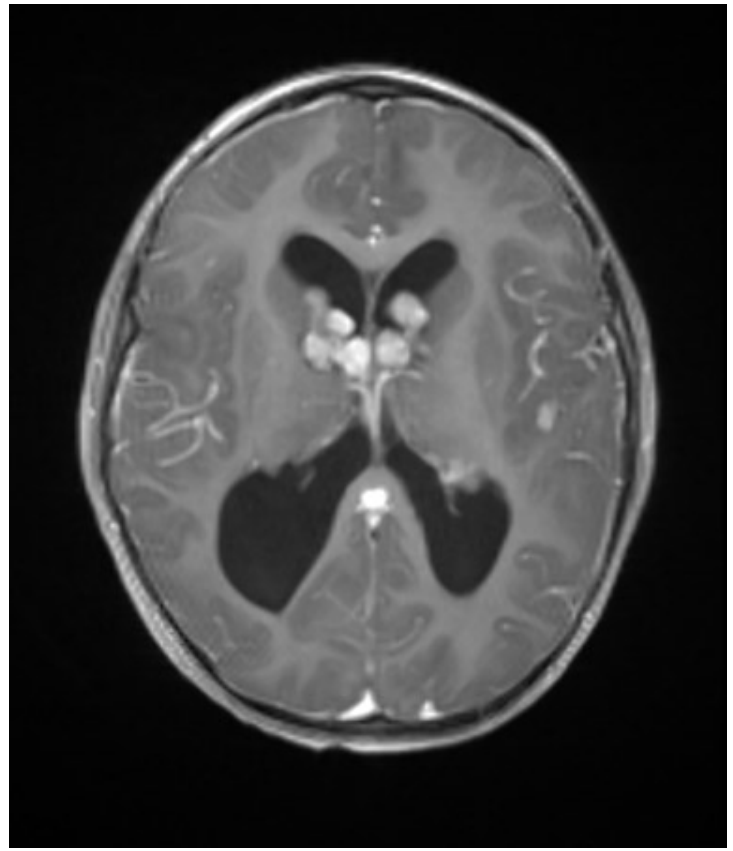

Irregular Characteristics

Molecular Basis of TSC

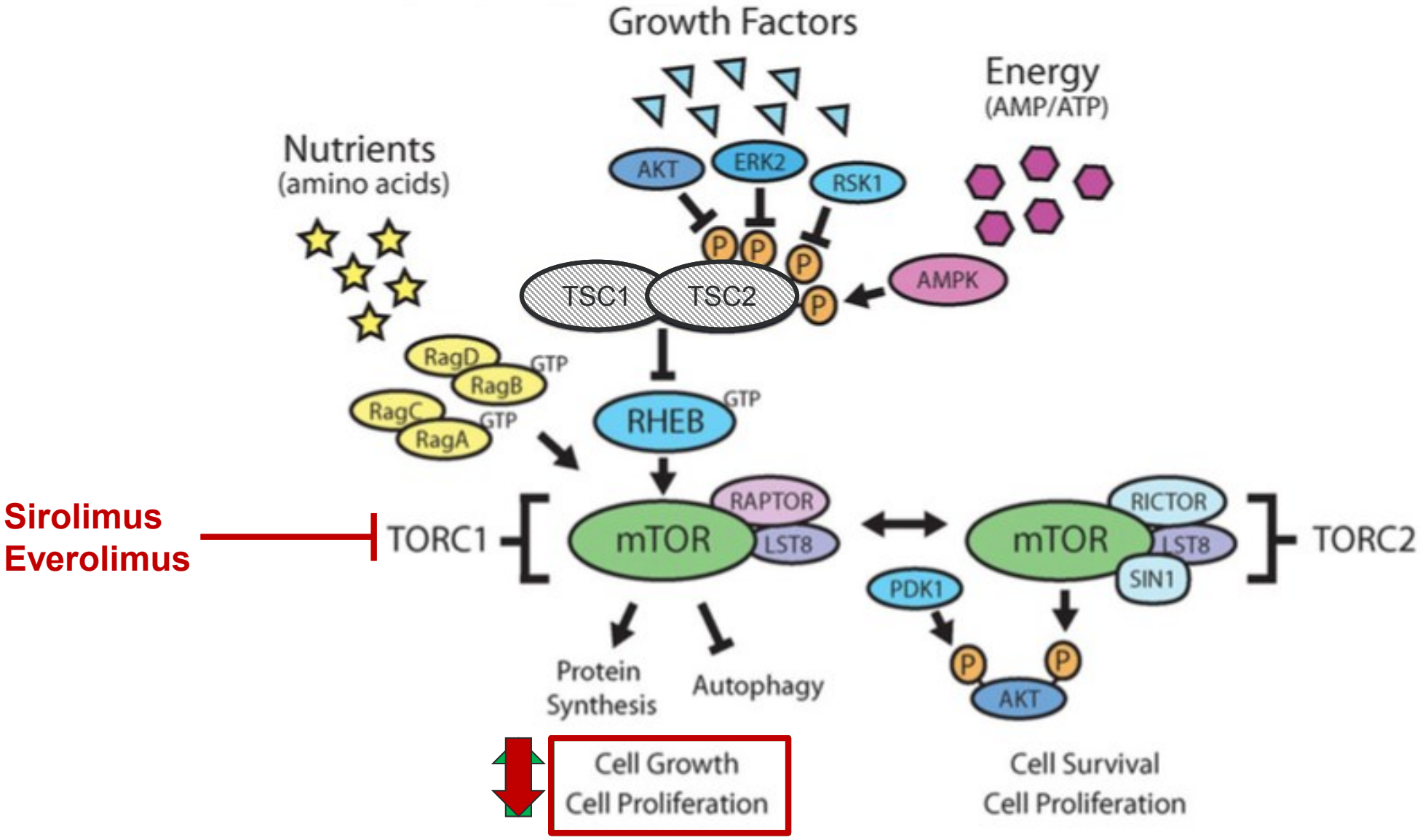

Approved mTOR Inhibitors for TSC (2019)

	Subependymal Giant Cell Astrocytoma (SEGA)	Renal Angiomyolipoma	Lymphangioleiomyomatosis (LAM)	Refractory Epilepsy
United States (FDA)	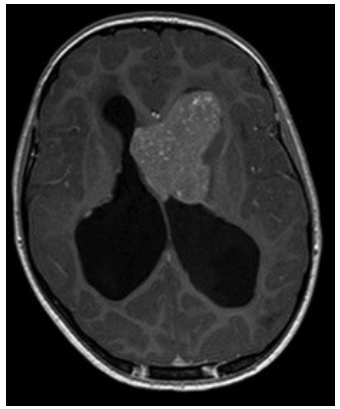			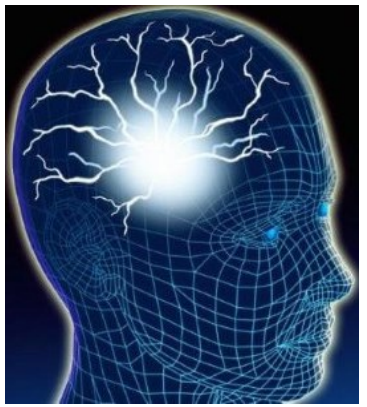
European Union (EMA)	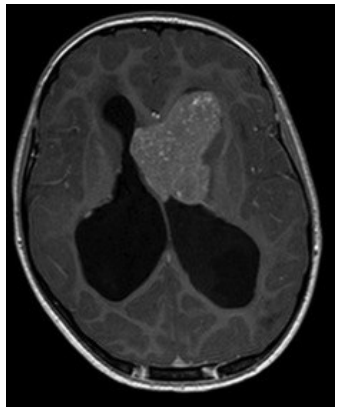			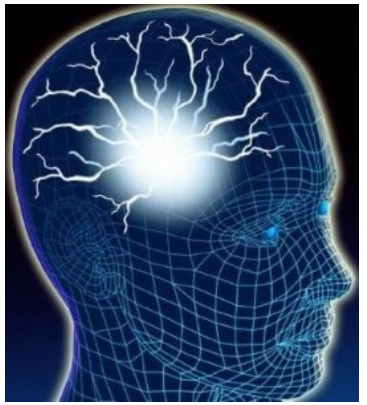
	Everolimus	Everolimus	Sirolimus	Everolimus

Phase I/II: Everolimus for SEGA in TSC

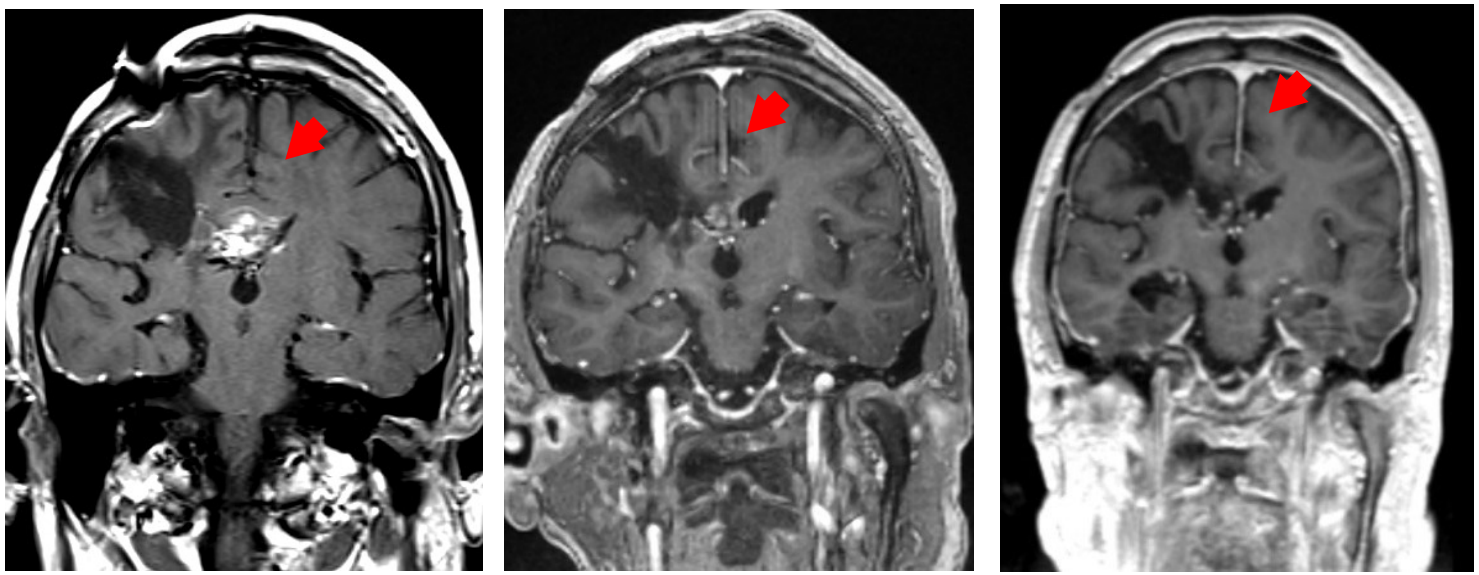



N = 28

Any Reduction: 28 (100%)
≥30% Reduction: 21 (75.0%)
≥50% Reduction: 9 (32.1%)

p<0.001

Krueger *et al. New Engl. J. Med.* 2010; Krueger *et al. Neurology.* 2013; Franz *et al. Annal Neurol* 2015.

Phase III: Everolimus for SEGA in TSC (EXIST-1)

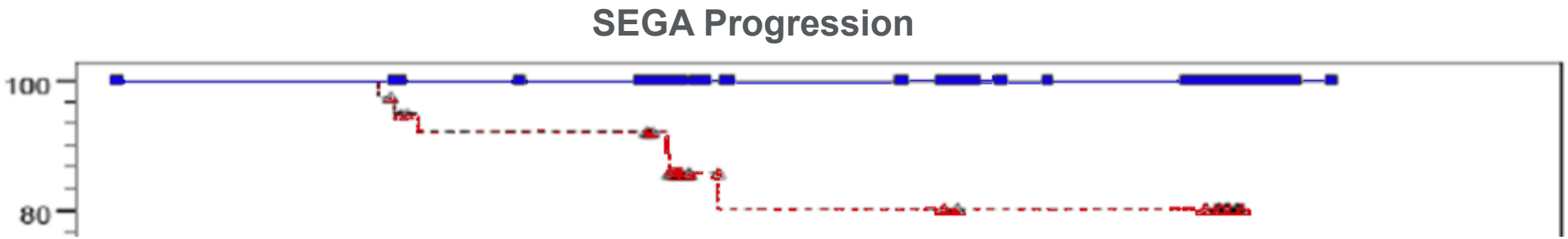

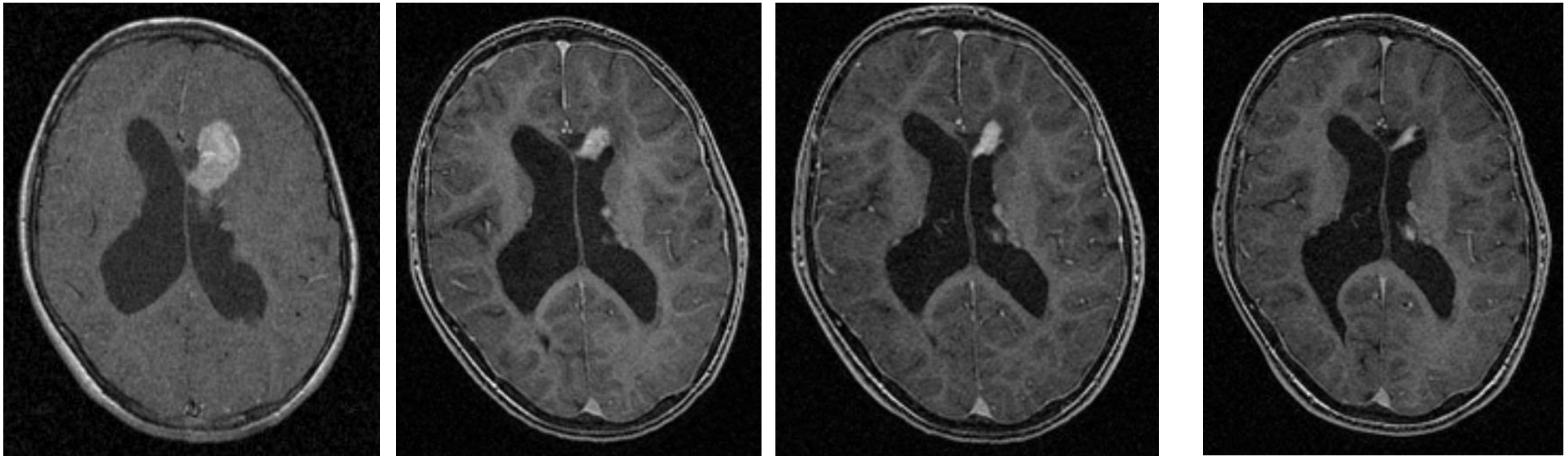

Baseline **3 months** **6 months** **48 months**

Franz *et al. Lancet.* 2012; ***Franz et al. Lancet Oncol. 2014 ;*** Franz et al, *PLoS One 2016*

Phase III: Long-term Treatment with Everolimus (EXIST-1) Adverse Events (AE)

AE Category	N (%)
Stomatitis	47 (42%)
Mouth ulcers	32 (29%)
Pneumonia	14 (13%)
Increased cholesterol	11 (10%)
Pyrexia	10 (9%)
URI	10 (9%)
Neutropenia	9 (8%)
Otitis media	9 (8%)
Cough	9 (8%)
Hypercholesterolemia	8 (7%)
Nasopharyngitis	8 (7%)
Increased LDL	7 (6%)
Increased TG	6 (5%)
Decreased appetite	6 (5%)
Fatigue	6 (5%)

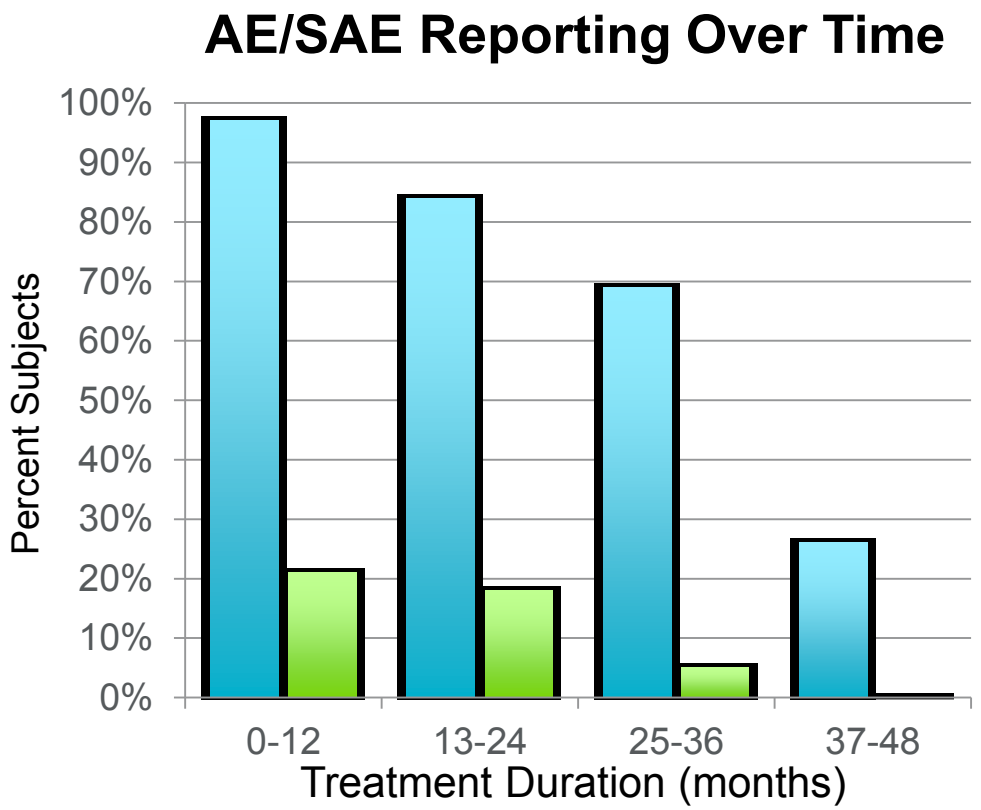

Franz et al. *Lancet Oncology 2014*

EUROPEAN JOURNAL OF PAEDIATRIC NEUROLOGY 22 (2018) 1066–1073

ELSEVIER

Official Journal of the European Paediatric Neurology Society







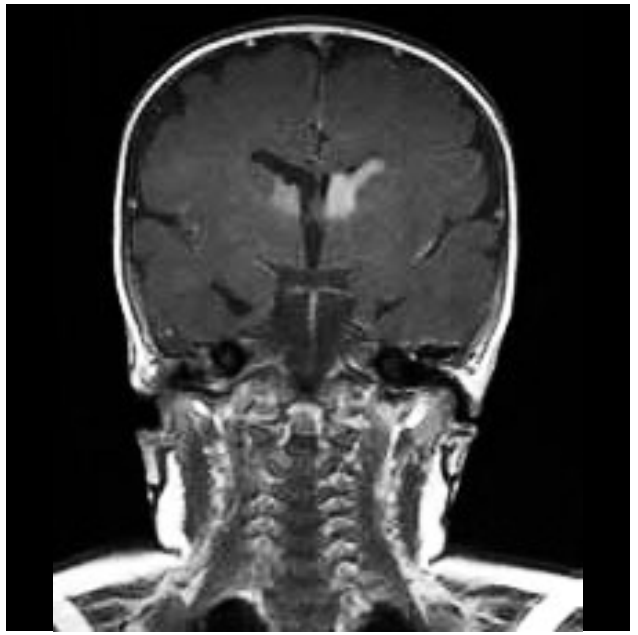

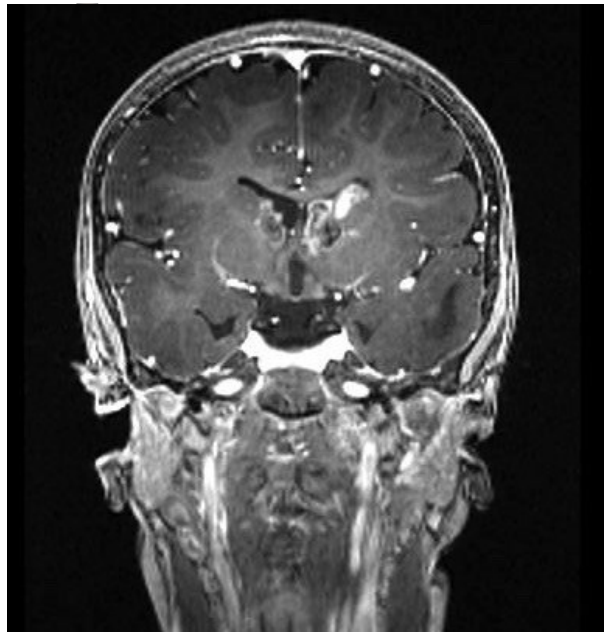

1 DAY **5 DAYS** **5 MONTHS** **44 MONTHS**

Everolimus initiated on day 28

Are mTOR inhibitors safe for TSC infants?

STOPPING TSC ONSET AND PROGRESSION: Safety of mTOR Inhibitors in TSC Infants (STOP-1)

Table 1: Adverse Events in TSC Infants 0-24 Months of Age Treated with Everolimus (N=45)

	Grade 1	Grade 2	Grade 3	Grade 4	Grade 5	SAE	Total AE	Ongoing AE
Ulcers/Stomatitis	2	11	1	0	0	0	14	0
URI/Sinusitis/Otitis	0	22	2	0	0	3	27	0
Gastroenteritis	0	6	1	0	0	0	7	0
Other infections	0	9	1	0	0	0	10	0
Rash	0	10	0	0	0	0	10	1
Fever	0	7	0	0	0	0	7	0
Vomiting/Feeding	0	1	0	0	0	1	2	0
Behavior	0	2	0	0	0	0	2	0
Abnormal Complete Blood Count (CBC)	1	1	1	0	0	1	4	0
Abnormal Basic Metabolic Panel (BMP)	0	0	0	0	0	0	0	-
Elevated Cholesterol	3	1	1	0	0	0	5	3
Abnormal Hepatic Function (LFT)	0	0	0	0	0	0	0	-
Abnormal Urinalysis (UA)	0	1	0	0	0	0	1	0
Other AE or Laboratory Abnormality	0	0	0	0	0	0	0	-
TOTAL	**6**	**71**	**7**	**0**	**0**	**5**	**84**	**4**

Krueger *et al.* 2018. *European Journal of Paediatric Neurology* 22:1066-73

SEGA Natural History: Cincinnati Imaging Study

- Aynara Wulsin, MD PhD (University of Cincinnati)
- Frederico Ramos, MD (SJD Barcelona, Spain)
- Lorena Lechuga, MD (Mexico City, Mexico)







Cincinnati Children's
changing the outcome together

SEGA Natural History: Cincinnati Imaging Study

The results shared for this study were preliminary. Although we believe the preliminary results to be accurate, the analysis is ongoing and not yet published. Therefore unable to include this portion of the presentation for sharing at this time.

Cincinnati Children's
changing the outcome together

Epilepsy



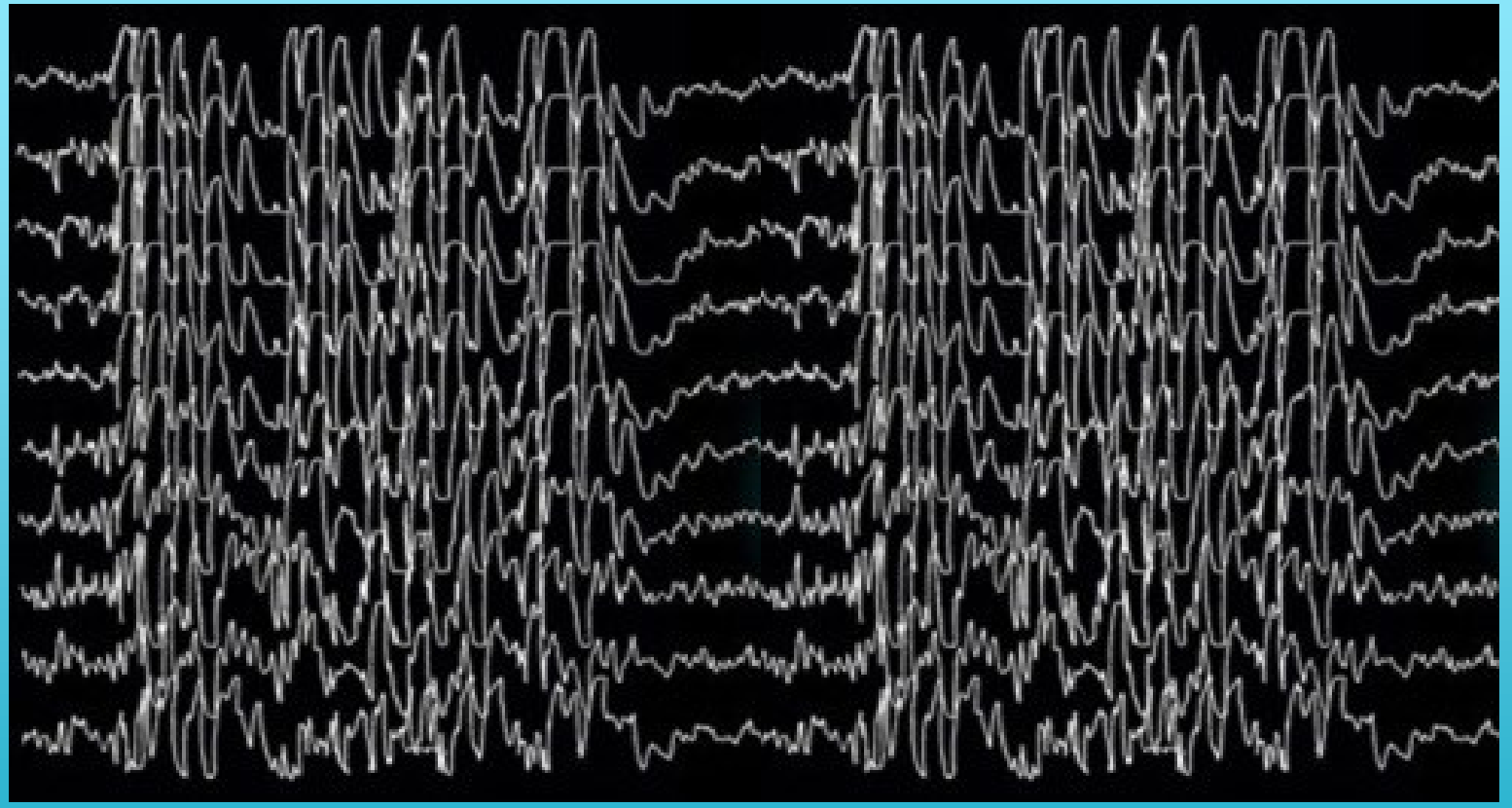

Natural History of Epilepsy in TSC

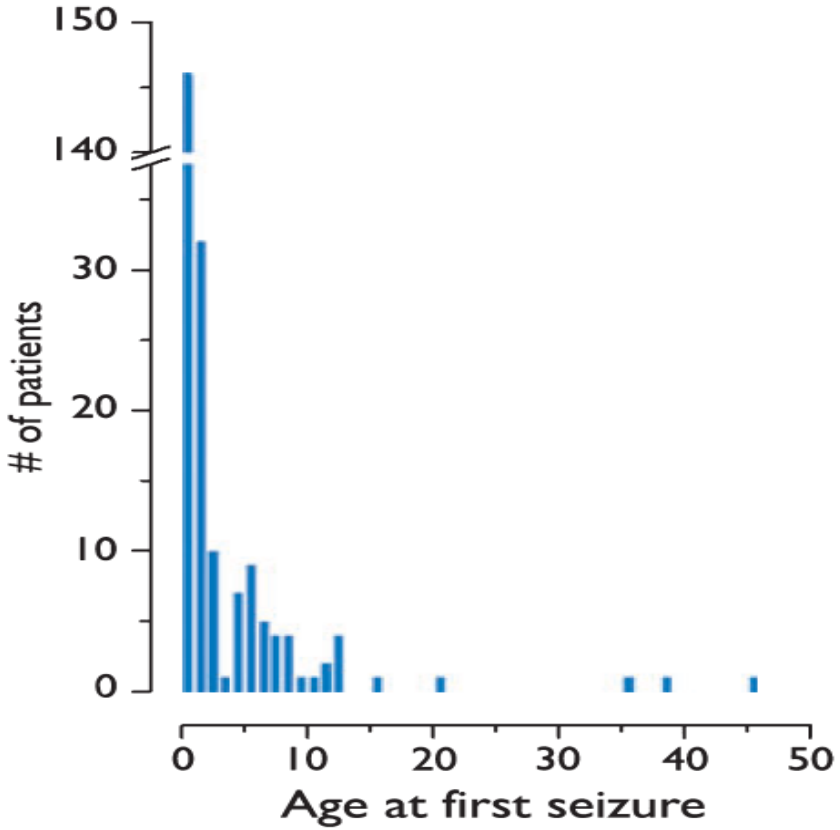

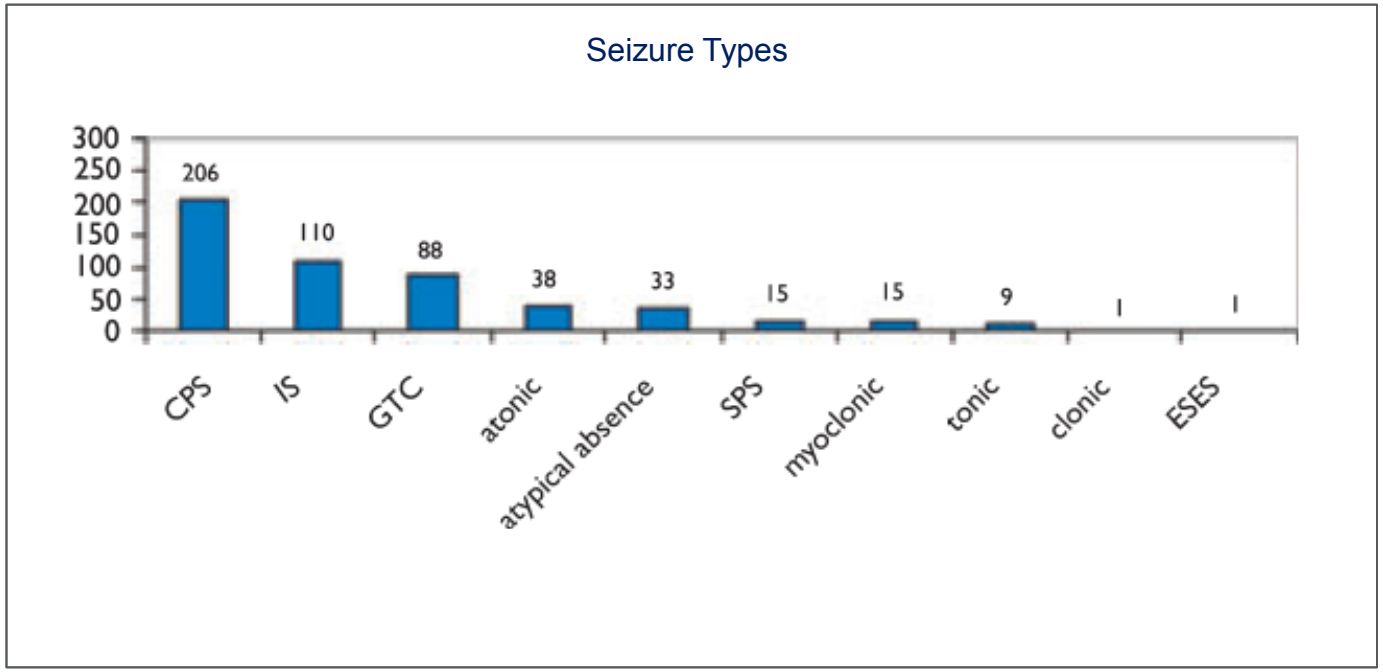

Chu-Shore et al. *Epilepsia* 2010;51:1236-1241.

Epilepsy Negatively Impacts Development in TSC

Mullen Scales of Early Learning

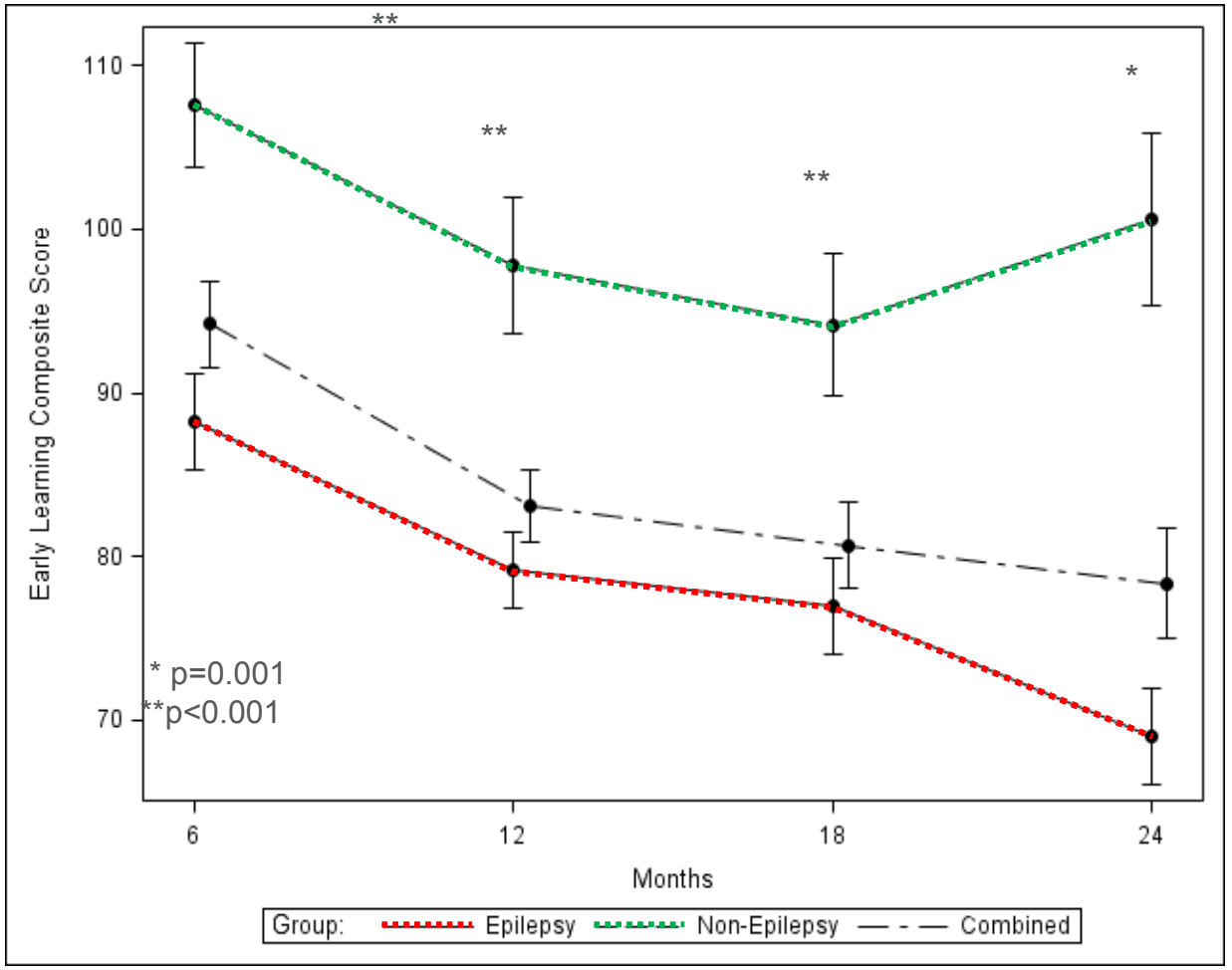

Autism Observation Scales

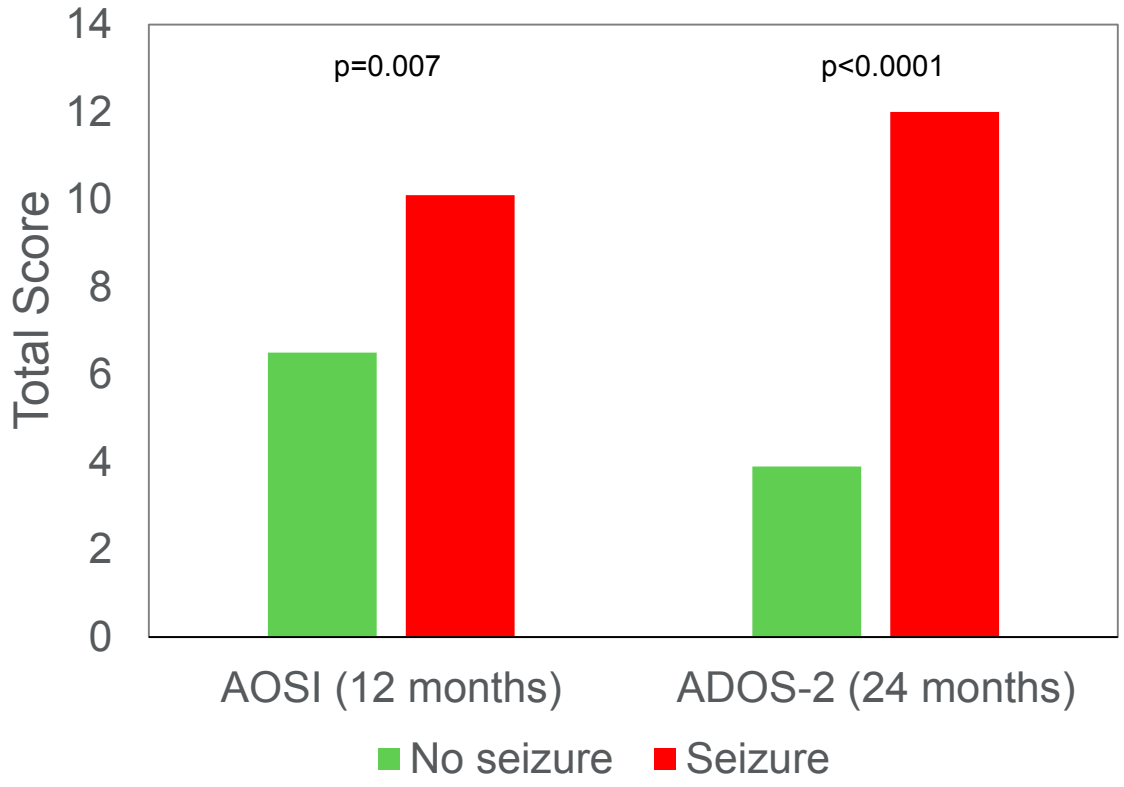

Capal *et al.* 2017. *Epilepsy and Behavior 70:245-252*

Approved Treatments for Epilepsy

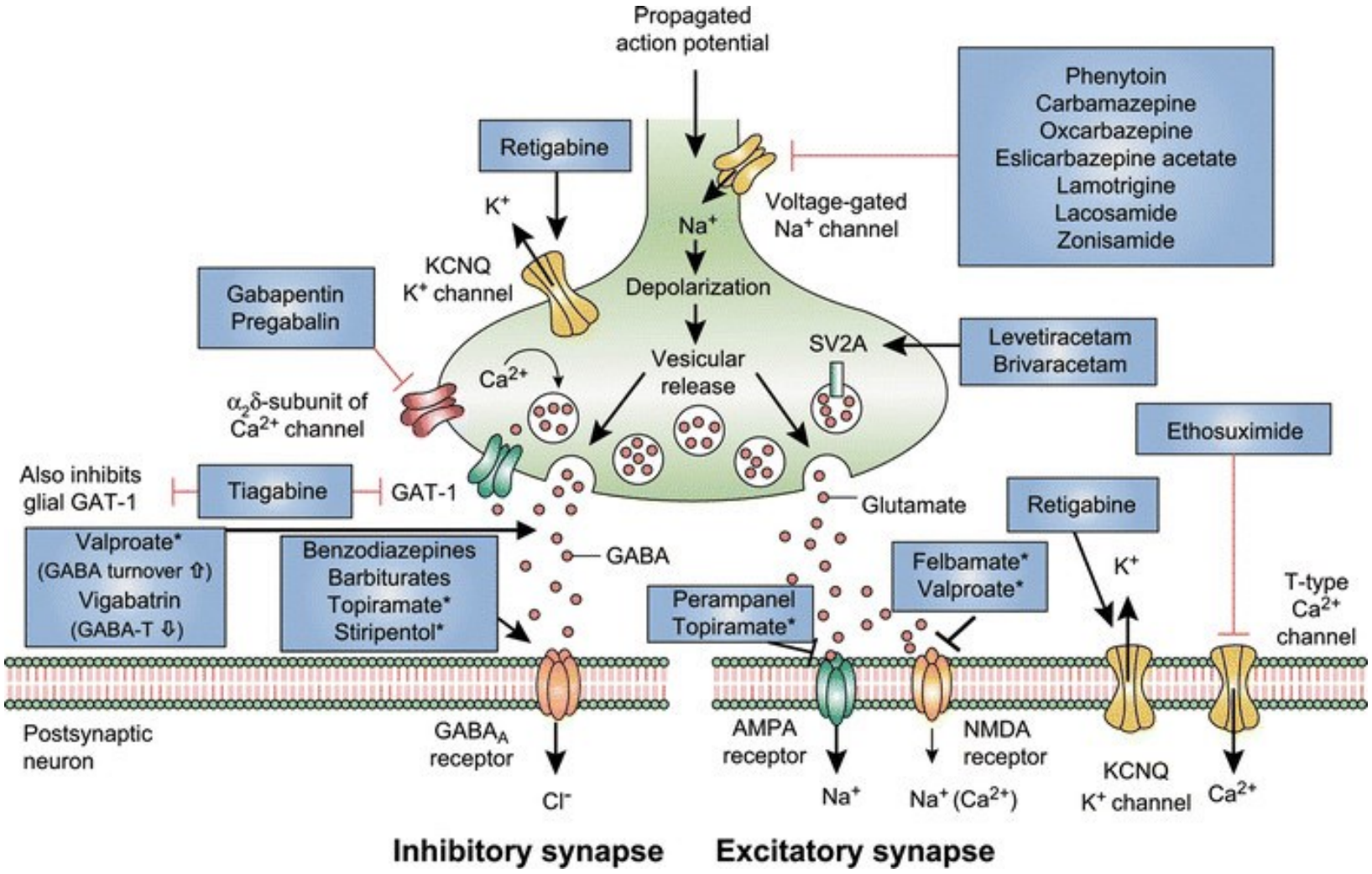

GABA signaling and regulation



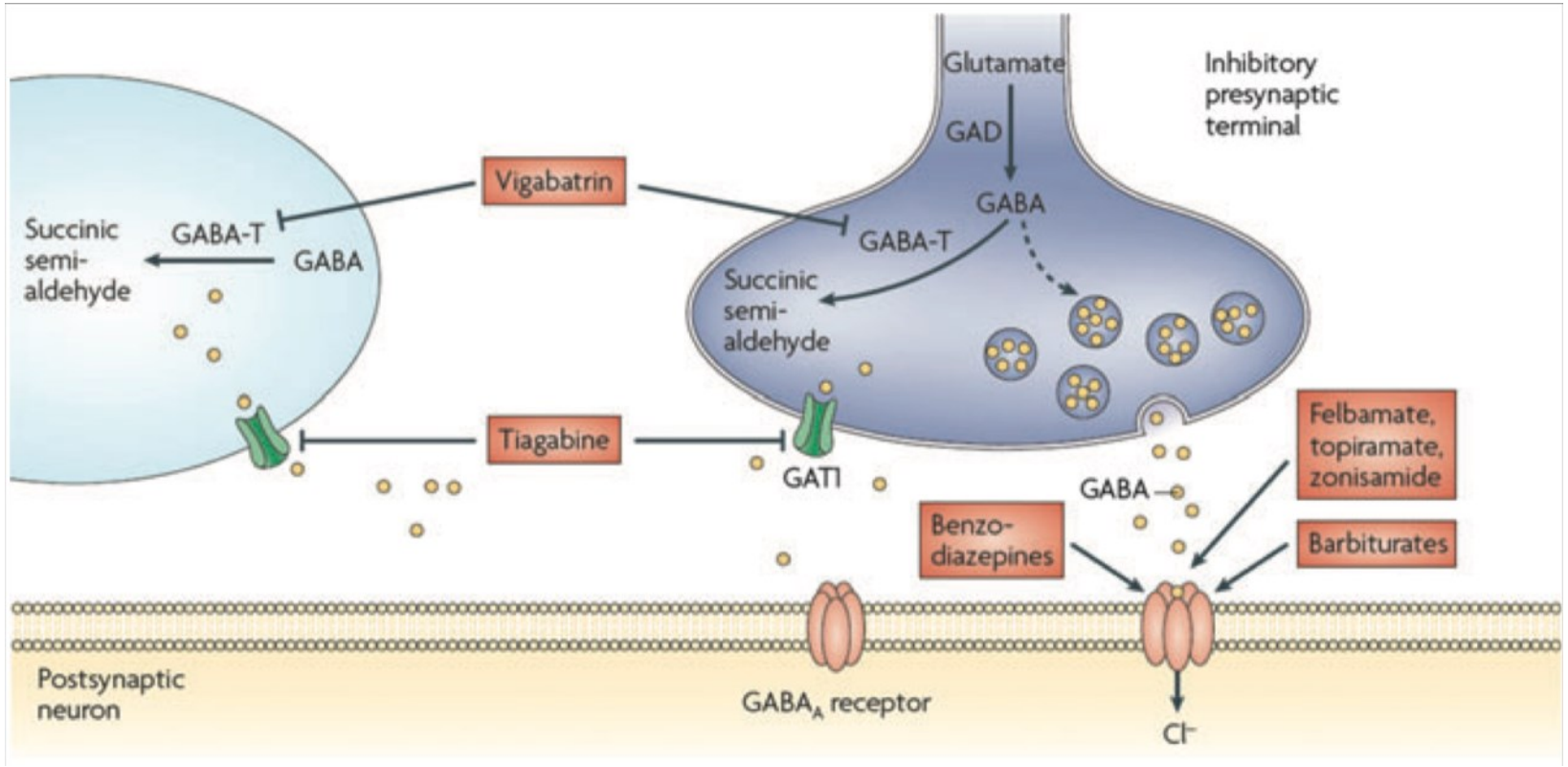

Ben-Menachem and Sander. *Acta Neurol Scand*. 2011;124:16-28.

Vigabatrin for Infantile Spasms in TSC

	Responders	Non-Responders
TSC (n = 77)	73 (95%)	4 (5%)
Non-TSC (n = 313)	169 (54%)	144 (46%)
Total (N = 390)	242 (62%)	148 (38%)

Hancock and Osborne. *J Child Neurol*. 1999;14:71-74.

	Responders	Non-Responders
TSC (n = 42)	31 (74%)	11 (26%)
Non-TSC (n = 26)	7 (27%)	19 (73%)
Total (N = 68)	38 (56%)	30 (44%)

Camposano *et al*. *Epilepsia* 2008;49:1186-1191.

Refractory Epilepsy in TSC

Table 3. Relationship of epilepsy prognosis to genetic mutation

	TSC1 (%)	*TSC2* (%)	NMI (%)
History of seizure[a]	51/60 (85)	112/123 (91.0)	34/48 (70.8)
Refractory epilepsy	27/51 (52.9)	76/112 (67.9)	20/34 (58.8)
Epilepsy remission[a]	17/50 (34.0)	34/122 (27.9)	18/31 (54.5)

[a]Denotes statistically significant comparison.

Chu-Shore et al. *Epilepsia* 2010;51:1236-1241.

Nonpharmacologic Treatments for Refractory Epilepsy in TSC

- Ketogenic/Modified Atkins Diet
- Vagus Nerve Stimulator
- Epilepsy Surgery

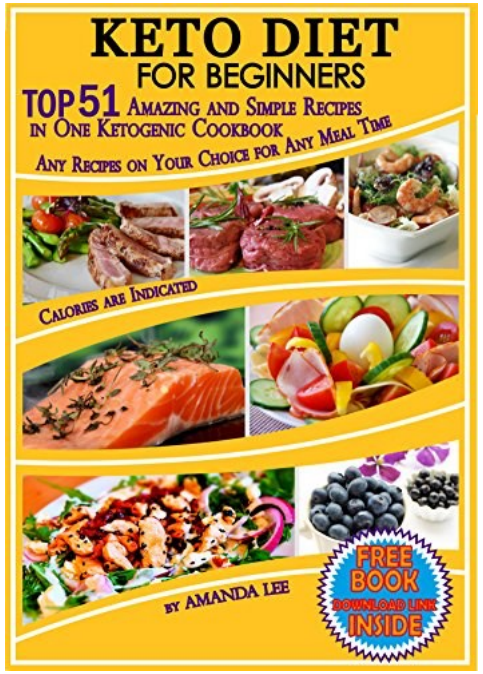

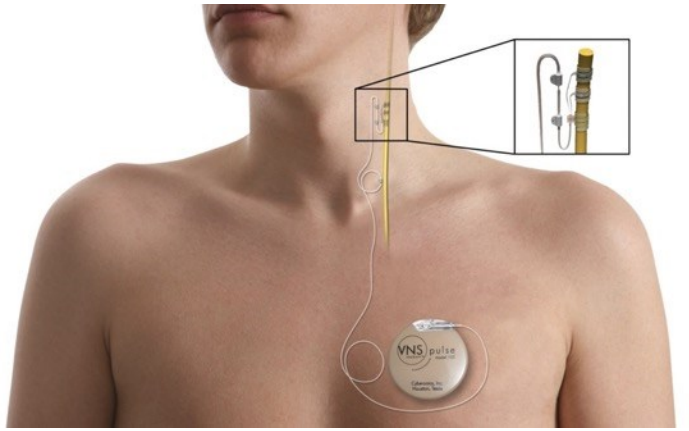



Phase I/II: Everolimus for Treatment of Epilepsy in TSC

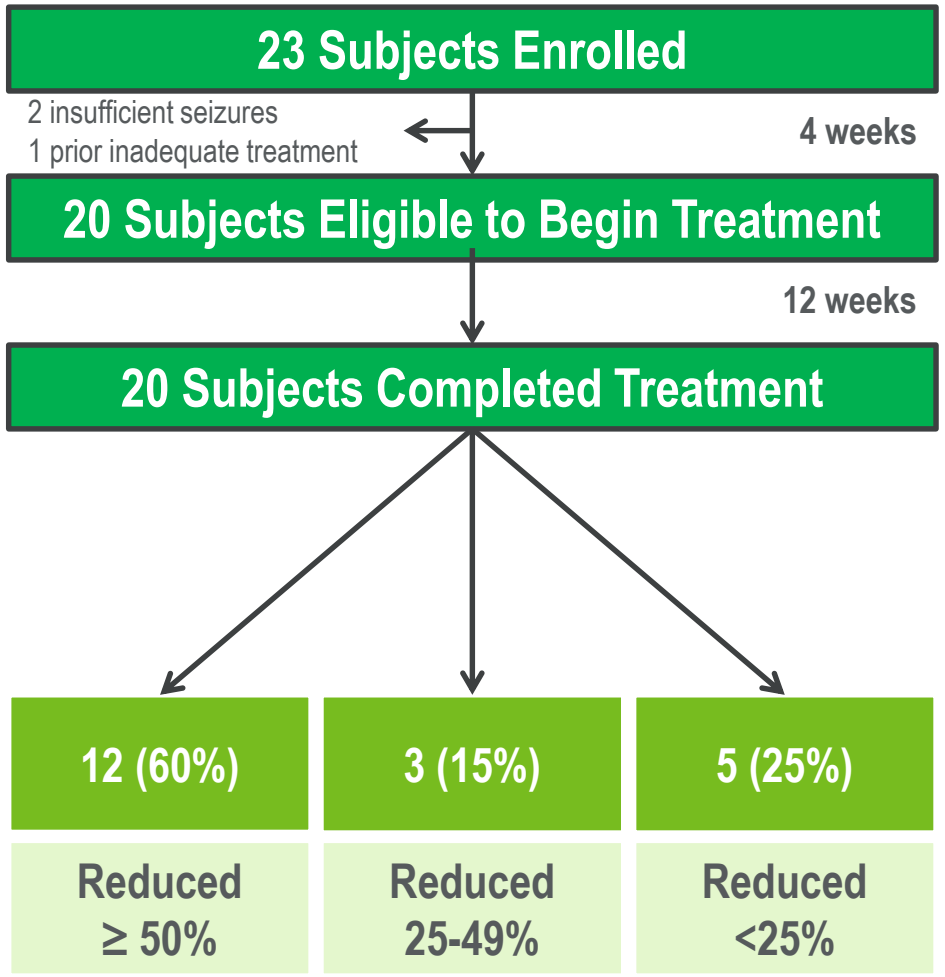

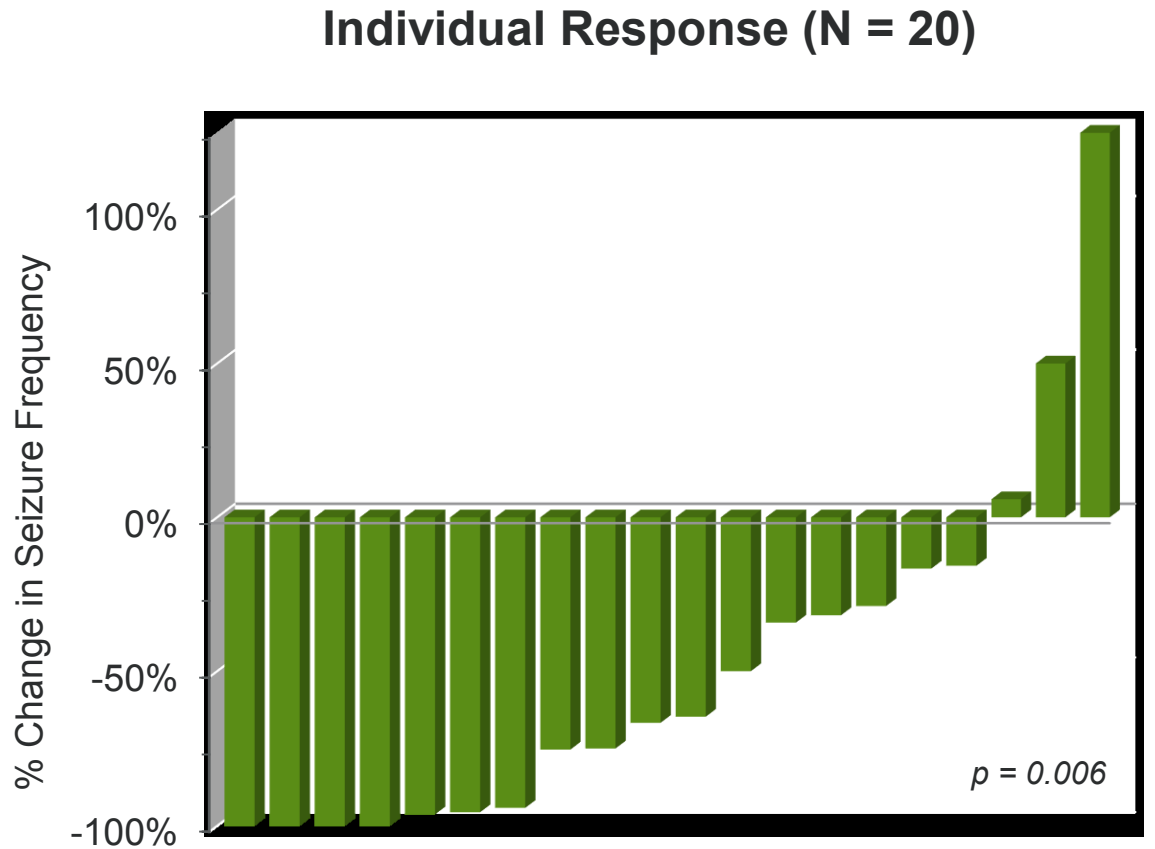

Krueger et al. Ann Neurol, 2013; Krueger et al. Neurology 2016

Phase III: Everolimus for Treatment of Epilepsy in TSC
(EXIST-3)

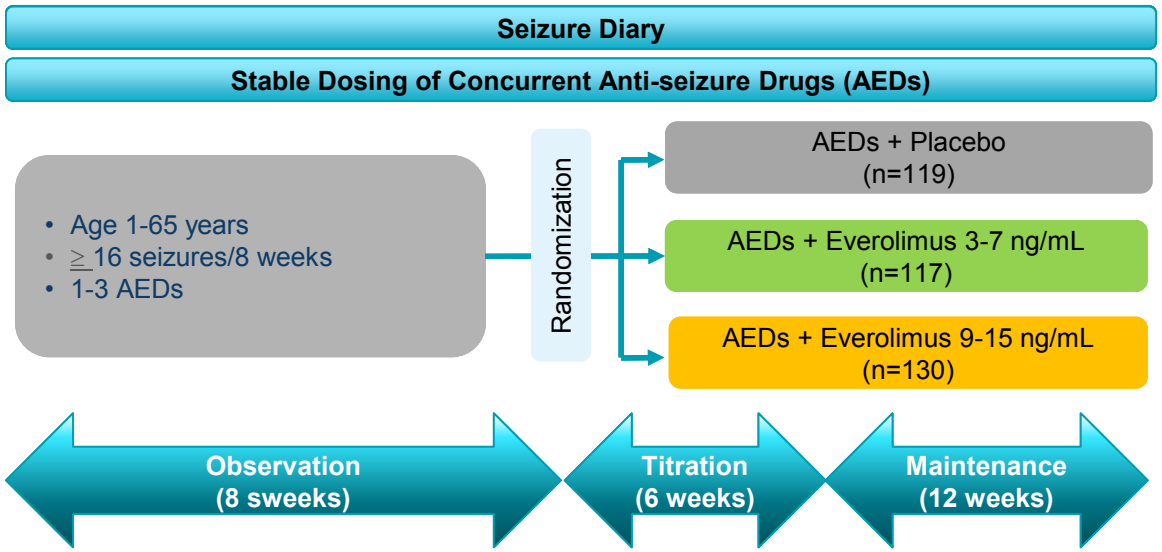

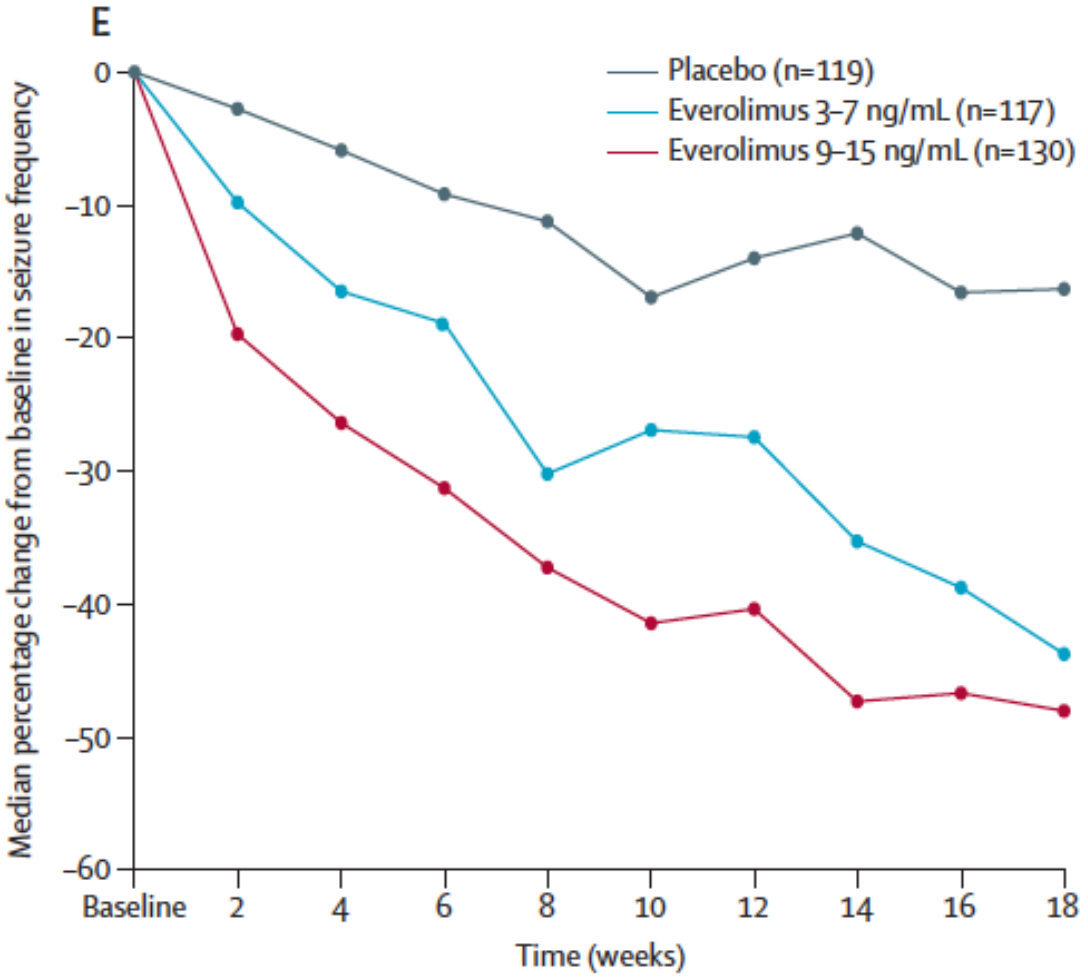

French JA et al. Lancet (2016). 388:2153-63.

EXIST-3: Everolimus for Epilepsy in TSC (Phase III)

Treatment Duration Impact on Seizure Frequency

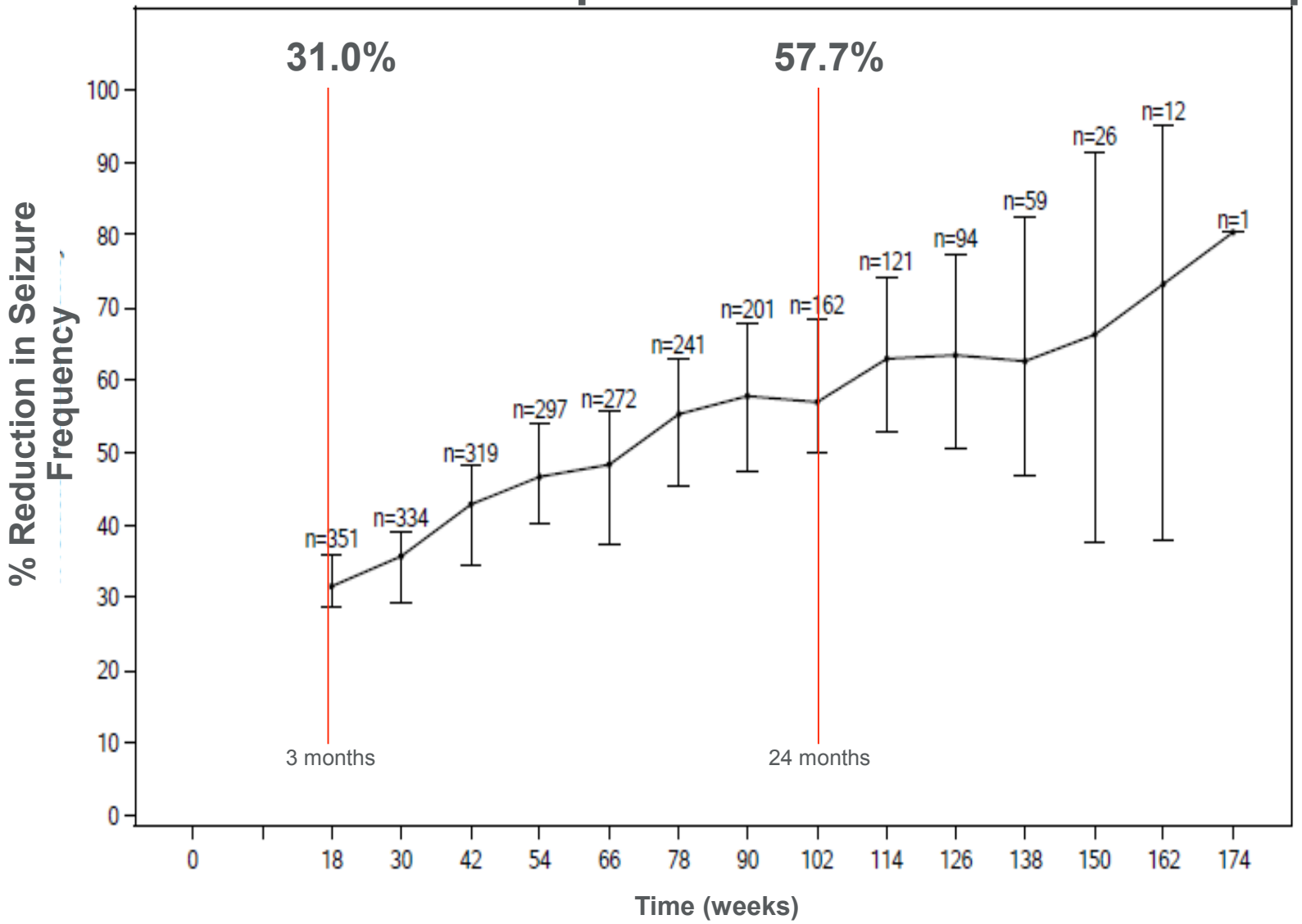

- Vertical bars are 95% CI of the median based on bootstrap percentiles.

Franz et al. Neurology Clin Pract. 2018

EXIST-3: Everolius for Treatment of Epilepsy in TSC (Phase III)

Adverse Events (Clinical and Laboratory: Long-term)

AE Category	N (%)
Stomatitis/Mouth ulcers	246 (68%)
Fever	125 (35%)
Diarrhea	103 (29%)
Nasopharyngitis	86 (24%)
URI	81 (22%)
Vomiting	72 (20%)
Cough	69 (19%)
Hypercholesterolemia	49 (14%)
Headache	46 (13%)
Rash	42 (12%)
Pneumonia	39 (11%)
Pharyngitis	37 (10%)
Bronchitis	36 (10%)
Gastroenteritis	36 (10%)

Treatment-emergent AEs, SAEs, and pneumonia by year (any grade)

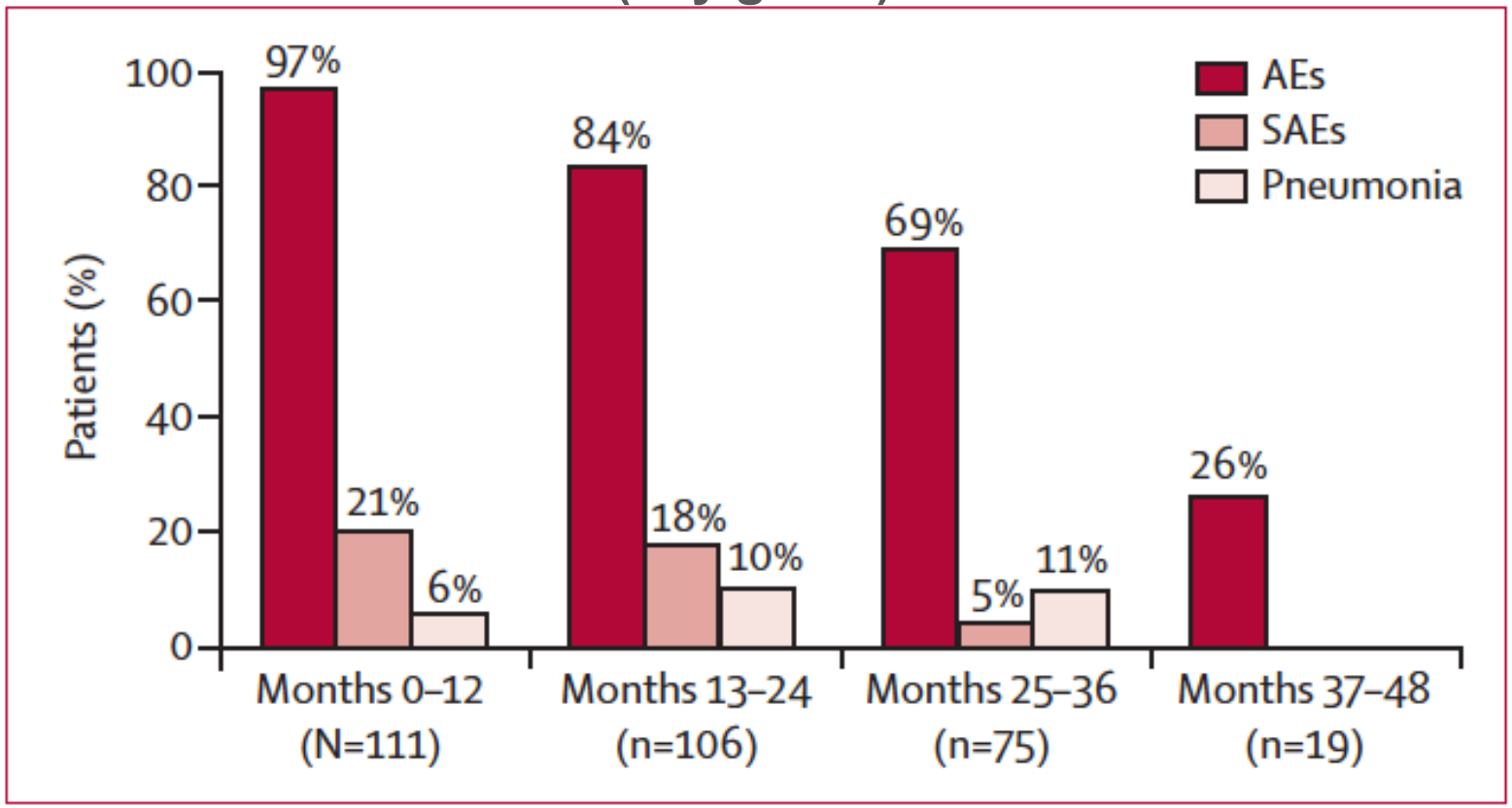

Franz et al. *Neurology: Clinical Practice*. 2018

Drug interactions

Carbamazepine
Oxcarbazepine
Phenobarbital
Phenytoin



Everolimus
Sirolimus
5-15 ng/ml



Grapefruit
Blood Oranges
Clarithromycin
Indinavir
Itraconazole
Ketaconazole
Voriconazole
Nefazodone
Cannabidiol

Cincinnati Children's
changing the outcome together

Summary

- SEGA occur in the first two decades of life in patients with TSC. Untreated, SEGA can be life-threatening. Surveillance imaging is needed every 1-3 years to monitor for emergence of SEGA.
- Everolimus is safe and effective treatment for SEGA and is now approved by the EMA as an alternative to surgery

- Epilepsy is common in TSC, impacts overall learning and development, and often is resistant to standard treatments.
- Everolimus is safe and effective treatment for partial seizures in TSC and is now EMA approved to treat epilepsy.

Cincinnati Children's
changing the outcome together

Dank je
Merci



krueger_darcy@cchmc.org

Cincinnati Children's
changing the outcome together